Feierabendhaus 2018

Anomalien der AV Klappen und des Septums

Folien bei m.meyer-wittkopf@mathias-spital.de

ULTRASCHALL- UNTERSUCHUNGEN

Bemerkungen: (z.B. Ergebnisse aus vorausgegangener Ultraschalluntersuchung)

Datum	SSW (LR)	SSW korrigiert	I. Screening 8 + 0 bis 11 + 6 SSW					FS	SSL	BPD	Biometrie I
			Intrauteriner Sitz:	❍ ja	❍ nein	Zeitgerechte Entwicklung:	❍ ja ❍ nein				
			Embryo darstellbar:	❍ ja	❍ nein		❍ Kontrolle				
			Herzaktion:	❍ ja	❍ nein						
			Mehrlinge:	❍ nein	❍ ja						
			monochorial:	❍ nein	❍ ja	Konsiliaruntersuchung veranlasst:	❍ nein ❍ ja	Bemerkungen:			
			Auffälligkeiten:	❍ ja ❍ nein	❍ Kontrolle						

Datum	SSW (LR)	SSW korrigiert	II. Screening 18 + 0 bis 21 + 6 SSW					BPD	FOD/KU	ATD	APD/AU	FL
			a)			**Thorax:**						
			Einling:	❍ ja	❍ nein	Auffällige Herz/Thorax-Relation (Blickdiagnose)	❍ ja ❍ nein					
			Herzaktion:	❍ ja	❍ nein							
			Plazentalok./-struktur:	❍ normal	❍ Kontrolle	Linksseitige Herzposition	❍ ja ❍ nein					
			Kommentar:			Persistierende Arrhytmie im Untersuchungszeitraum	❍ ja ❍ nein	**Kontrollbedürftige Befunde hinsichtlich**				
			Zeitgerechte Entwicklung:	❍ ja ❍ nein	❍ Kontrolle	Darstellbarkeit des Vier-Kammer-Blicks	❍ ja ❍ nein	Fruchtwassermenge:	❍ nein	❍ ja		
			b)					körperl. Entwicklung:	❍ nein	❍ ja		
			Kopf:			**Rumpf:**						
			Ventrikelauffälligkeiten	❍ ja	❍ nein	Konturunterbrechung an der vorderen Bauchwand	❍ ja ❍ nein	Konsiliaruntersuchung veranlasst:	❍ nein	❍ ja		
			Auffälligkeiten der Kopfform	❍ ja	❍ nein							
			Darstellbarkeit des Kleinhirns	❍ ja	❍ nein	Darstellbarkeit des Magens im linken Oberbauch	❍ ja ❍ nein	Bemerkungen:		Biometrie II		
			Hals und Rücken:									
			Unregelmäßigkeiten der dorsalen Hautkontur	❍ ja	❍ nein	Darstellbarkeit der Harnblase	❍ ja ❍ nein					

Datum	SSW (LR)		III. Screening 28 + 0 bis 31 + 6 SSW			**Kontrollbedürftige Befunde hinsichtlich**		BPD	FOD/KU	ATD	APD/AU	FL
			Einling:	❍ ja	❍ nein	Fruchtwassermenge:	❍ nein ❍ ja					
			Kindslage:			körperl. Entwicklung:	❍ nein ❍ ja					
			Herzaktion:	❍ ja	❍ nein							
			Plazentalok./-struktur:	❍ normal	❍ Kontrolle			Bemerkungen:		Biometrie III		
			Kommentar:									
			Zeitgerechte Entwicklung:	❍ ja	❍ nein ❍ Kontrolle	Konsiliaruntersuchung veranlasst:	❍ nein ❍ ja					

Häufigkeitsverteilung angeborener Herzfehler postnatal (→ = imVierkammerblick erkennbar)

Herzfehler	Lebend-geburten
Ventrikelseptumdefekt	32%
Pulmonalstenose	9%
Atrioventrikulärer Septumdefekt (AVSD)[a]	7%
Aortenisthmusstenose	5%
Fallot-Tetralogie	7%
Hypoplastisches Linksherzsyndrom (HLHS)[a]	4%
d-Transposition der großen Arterien	5%
Aortenklappenstenose	3%
„Univentrikuläres Herz" (Double Inlet etc.)[a]	2–3%
Double Outlet Right Ventricle (DORV)	2%
Pulmonalklappenatresie bei intaktem Ventrikelseptum[a]	2%
Truncus arteriosus	1%

(Hoffman, Pediatr Cardiol 1995)

Geburten, Ultraschall und Herzfehler 2016 in der BRD

Praenatal

Klinik-Geburtenzahl	760.652
Anteil US II B	95-100 %
01774 / A1007 (Berlin)	95 %
Prävalenz Herzfehler	0,8-0.9 %
… davon übersehen	65 %

eine Katastrophe !

Screenshot 20.01.2018 PD Dr Stressig
Pränatalsymposium Giessen

Sonografische Darstellbarkeit der fetalen Anatomie in Abhängigkeit vom BMI

	Vollständige Ultraschalluntersuchung				
	BMI <25	BMI 25–29	BMI 30–34	BMI 35–39	BMI ≥40
Dashe et al. 2009 (13)	72 %	68 %	57 %	41 %	30 %
Thornburg et al. 2009 (26)*					
– Basic Scan	79 % (58 %)	76 % (49 %)	72 % (41 %)	61 % (23 %)	49 % (17 %)
– Comprehensive Scan	43 % (16 %)	40 % (11 %)	38 % (8 %)	41 % (6 %)	31 % (4 %)
vollständige „genetische Sonografie" (Tsai et al. 2010 (27))	63 %	62 %	58 %	51 %	41 %
Entdeckungsrate schwerer Fehlbildungen (Dashe et al. 2009 (13))	66 %	49 %	48 %	42 %	25 %

* In der Studie von Thornburg et al. (26) schloss der „Basic Scan" 12 darzustellende Strukturen ein, der „Comprehensive Scan" 6 weitere (Lippen/Nase, Profil, Hände, Füße, RVOT und LVOT); die Prozentzahlen geben die kumulative Erfolgsrate bei wiederholten Untersuchungen an, die Prozentzahlen in Klammern die bei der ersten Untersuchung.

Tab. 2: Anteil der Schwangeren unterschiedlicher Gewichtskategorien (BMI in kg/m²), bei denen die vollständige Darstellung der fetale Anatomie mit 18–22 SSW gelang

Herzfehler BRD + CH aktuell 2018

- keine Risikofaktoren für CHD eruierbar bei 80-90 % der Mütter

- Bei ca. 30-50% zusätzlich **extrakardiale Fehlbildungen**
- **Aneuploidien** bei mind. 20-25% der Kinder mit Herzfehlern
-

Circulation

American Heart Association.

Diagnosis and Treatment of Fetal Cardiac Disease: A Scientific Statement From the American Heart Association

Mary T. Donofrio, Anita J. Moon-Grady, Lisa K. Hornberger, Joshua A. Copel, Mark S. Sklansky, Alfred Abuhamad, Bettina F. Cuneo, James C. Huhta, Richard A. Jonas, Anita Krishnan, Stephanie Lacey, Wesley Lee, Erik C. Michelfelder, Sr, Gwen R. Rempel, Norman H. Silverman, Thomas L. Spray, Janette F. Strasburger, Wayne Tworetzky and Jack Rychik on behalf of the American Heart Association Adults With Congenital Heart Disease Joint Committee of the Council on Cardiovascular Disease in the Young and Council on Clinical Cardiology, Council on Cardiovascular Surgery and Anesthesia, and Council on Cardiovascular and Stroke Nursing

Circulation. 2014;129:2183-2242; originally published online April 24, 2014;
doi: 10.1161/01.cir.0000437597.44550.5d
Circulation is published by the American Heart Association, 7272 Greenville Avenue, Dallas, TX 75231
Copyright © 2014 American Heart Association, Inc. All rights reserved.
Print ISSN: 0009-7322. Online ISSN: 1524-4539

Table 10. Risk of Aneuploidy With Selected Cardiac Malformations

Lesion	Risk, %[113,360,380]
Atrioventricular septal defect	46–73
Coarctation/arch interruption	5–37
Double-outlet right ventricle/conotruncal malformations	6–43
Hypoplastic left heart syndrome	4–9
Heterotaxy/cardiosplenic syndromes	0
Pulmonic stenosis/atresia with intact septum	1–12
Transposition of great arteries	0
Tetralogy of Fallot	7–39
Truncus arteriosus	19–78
Tricuspid valve dysplasia (including Ebstein malformation)	4–16

Ultrasound Obstet Gynecol 2013; 41: 348–359
Published online in Wiley Online Library (wileyonlinelibrary.com). DOI: 10.1002/uog.12403

isuog.org GUIDELINES

ISUOG Practice Guidelines (updated): sonographic screening examination of the fetal heart

Table 1 Assessment of fetal situs/laterality and the four-chamber view

Situs and general aspects
Fetal laterality (identify right and left sides of fetus)
Stomach and heart on left
Heart occupies a third of thoracic area
Majority of heart in left chest
Cardiac axis (apex) points to left by 45° ± 20°
Four chambers present
Regular cardiac rhythm
No pericardial effusion
Atrial chambers
Two atria, approximately equal in size
Foramen ovale flap in left atrium
Atrial septum primum present (near to crux)
Pulmonary veins entering left atrium
Ventricular chambers
Two ventricles, approximately equal in size
No ventricular wall hypertrophy
Moderator band at right ventricular apex
Ventricular septum intact (apex to crux)
Atrioventricular junction and valves
Intact cardiac crux
Two atrioventricular valves open and move freely
Differential offsetting: tricuspid valve leaflet inserts on ventricular septum closer to cardiac apex than does mitral valve

Aplio 500
Mathias-Spital Rheine
OB 6 MW
07:54:13
Precision
A Pure+
T
MI
1.5
10C3
diffT6.0
24 fps
G:79
DR:60
5

Was liegt wo?



Situs solitus

Situs ambiguus

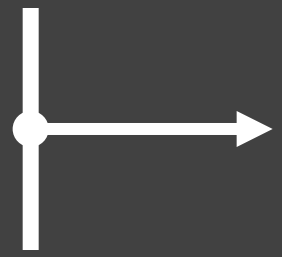

Situs inversus

Sehr häufig assoziiert mit strukturellen Fehl-Bildungen des Herzens

TOSHIBA
Mathias-Spital Rheine - - FHeart6
16:42:49
Precision
Pure
T
4
6
8
MI:0.7
2DG
71
DR
55
10C3
diffT6.0
60 fps
A 3 IP2
HDD:17% Free
Raw Memory:#0(0%)

Ultrasound Obstet Gynecol 2013; 41: 348–359
Published online in Wiley Online Library (wileyonlinelibrary.com). DOI: 10.1002/uog.12403

isuog.org GUIDELINES

ISUOG Practice Guidelines (updated): sonographic screening examination of the fetal heart

Table 1 Assessment of fetal situs/laterality and the four-chamber view

Situs and general aspects
Fetal laterality (identify right and left sides of fetus)
Stomach and heart on left
Heart occupies a third of thoracic area
Majority of heart in left chest
Cardiac axis (apex) points to left by 45° ± 20°
Four chambers present
Regular cardiac rhythm
No pericardial effusion
Atrial chambers
Two atria, approximately equal in size
Foramen ovale flap in left atrium
Atrial septum primum present (near to crux)
Pulmonary veins entering left atrium
Ventricular chambers
Two ventricles, approximately equal in size
No ventricular wall hypertrophy
Moderator band at right ventricular apex
Ventricular septum intact (apex to crux)
Atrioventricular junction and valves
Intact cardiac crux
Two atrioventricular valves open and move freely
Differential offsetting: tricuspid valve leaflet inserts on ventricular septum closer to cardiac apex than does mitral valve

- Im Normalfall nimmt das Herz
- ein Drittel des Thorax ein

- Herzumfang/Thoraxumfang (enddiastolisch) < 0,56

TOSHIBA
Aplio 800
Mathias-Spital Rheine
OB 10C3
14:15:12
Precision+
A Pure
MI
1.2
10C3
d7.6
31 fps
Qscan
G:81
DR:65
A:1
P:5
5

Precision
5

TOSHIBA
Aplio 500
10660633:Boekhoff Insa
Klinikum Oldenburg Frauenklin.
OB 1
F 24
PROF. MEYE
16.11.2017
13:10:21
Precision
A Pure+
T
0
5
10
12
MI
1.0
10C3
diffT6.0
21 fps
G:74
DR:65
A:4
P:1

Precision
A Pure+
T
0
5
10
MI
1.3
10C3
diffT6.0
23 fps
G:74
DR:65
A:4
P:1

T
4
6
8
10
12
6C2
T5.0
17 fps
MI:0.9
2DG
83
DR
60
Dist A 0.0 mm
HDD:12% Free

Aplio 500
Mathias-Spital Rheine
Fetal Heart
Meyer-Wittko
14:03:21
Precision
A Pure
T
MI
1.1
10C3
diffT6.0
48 fps
Qscan
G:82
DR:55
A:3
P:1
5

Aplio 500
Mathias-Spital Rheine
Fetal Heart
Meyer-Wittko
14:03:36
85.4
85.4
cm/s
5
Precision
A Pure
T
MI
1.2
10C3
diffT6.0
26 fps
Qscan
G:82
DR:55
CF 3.8
CG:35
8.4k
F:3

Ebstein Anomalie

* septales Segel

+ posteriores Segel

X atrialisierter RV

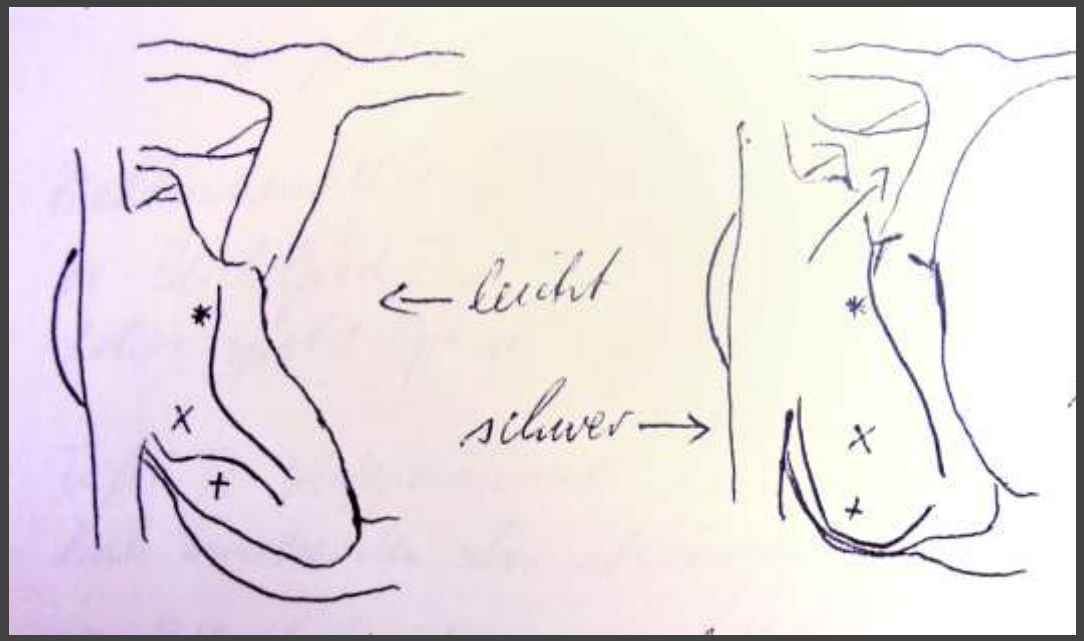

Figure 1

A pencil sketch of Wilhelm Ebstein published in the *Festschrift* celebrating Ebstein's 70th birthday. Published by permission of the Mayo Clinic Proceedings, where it was published by Mann RJ, Lie JT. The life story of Wilhelm Ebstein (1836–1912) and his almost overlooked description of a congenital heart disease. Mayo Clin Proc 1979;54:197–204.

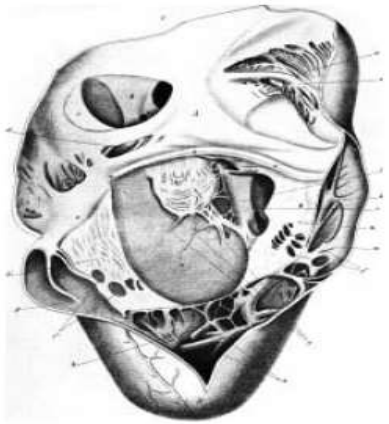

Figure 2

First figure of Ebstein's original case report. This figure shows right atrium and right ventricle opened along right border beginning at the superior vena cava. A = right atrium; B = right ventricle; b = valve not quite closing the foramen ovale, l = rudimentary septal leaflet of tricuspid valve with its chordae tendineae inserting on endocardium of ventricular septum; r = opening giving access to right conus arteriosus and, in the opposite direction, to the sac

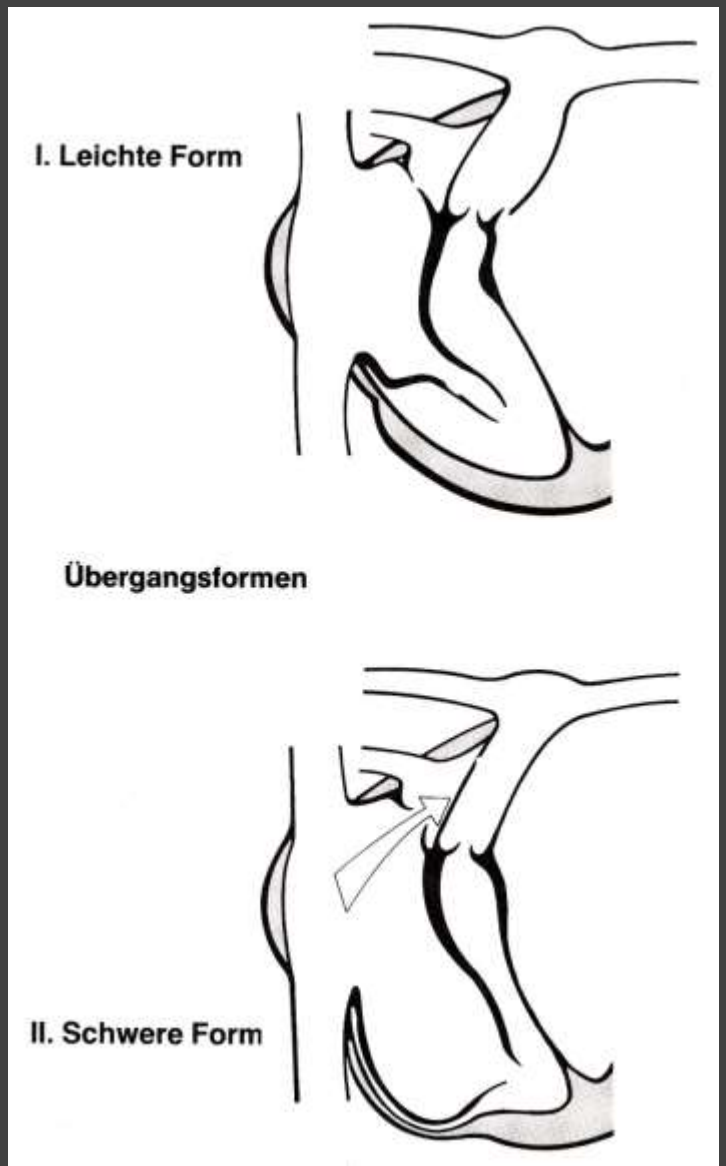

Aplio 500
Mathias-Spital Rheine
Fetal Heart
Meyer-Wittko
13:45:20
80.5
80.5
cm/s
5
Precision
A Pure
T
MI
1.4
10C3
diffT6.0
16 fps
Qscan
G:88
DR:55
CF 3.8
CG:35
8.0k
F:3

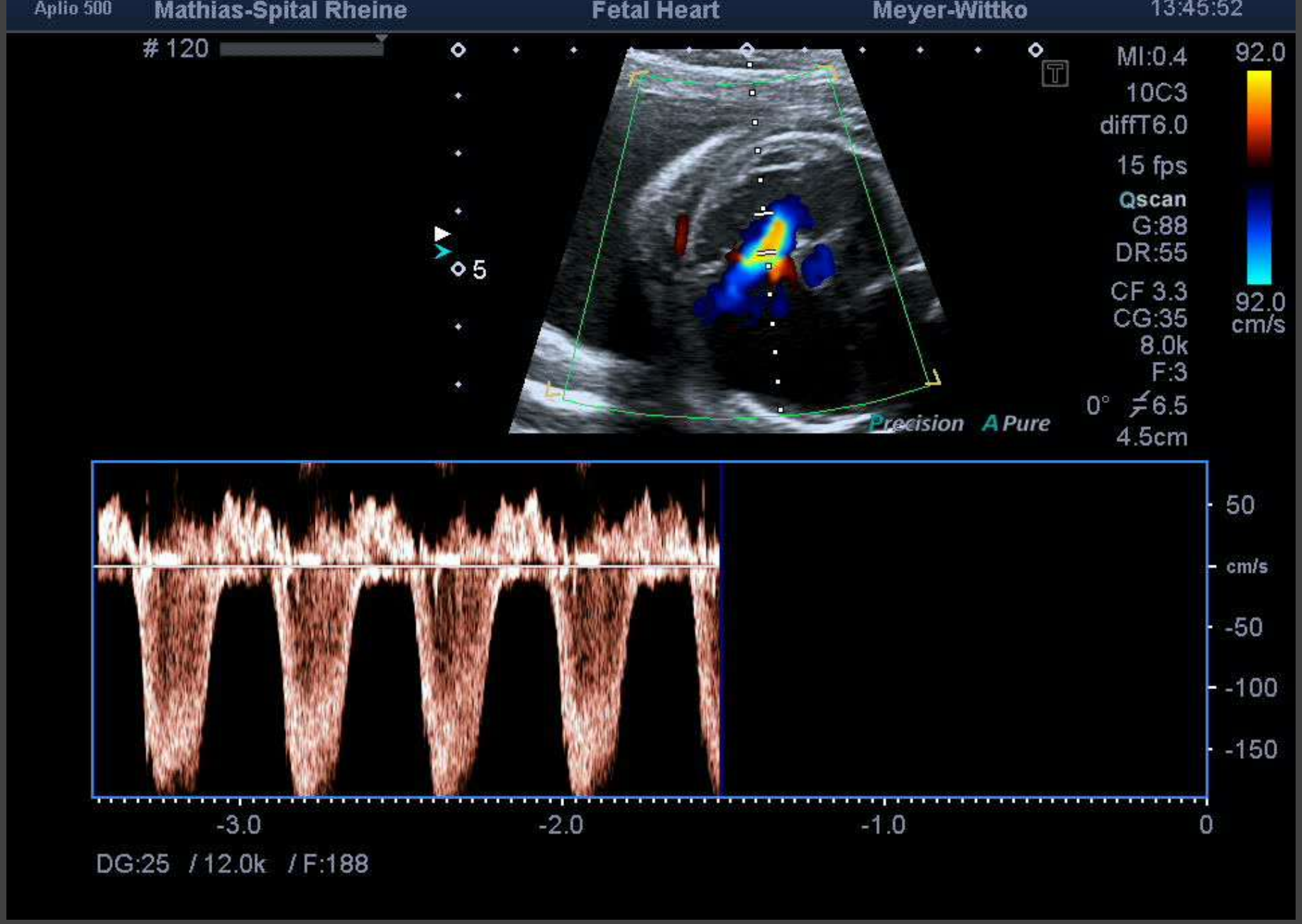
Aplio 500
Mathias-Spital Rheine
Fetal Heart
Meyer-Wittko
13:45:52
120
MI:0.4
10C3
diffT6.0
15 fps
Qscan
G:88
DR:55
CF 3.3
CG:35
8.0k
F:3
0°
6.5
4.5cm
92.0
92.0
cm/s
Precision
A Pure
50
cm/s
-50
-100
-150
-3.0
-2.0
-1.0
0
DG:25 / 12.0k / F:188

Aplio 500
Mathias-Spital Rheine
FHeart 3 MW
Meyer-Wittko
07:42:54
Precision
A Pure
T
0
5
10
14
MI
1.3
6C1
diffT5.0
25 fps
G:75
DR:55
A:3
P:1

Aplio 500
Mathias-Spital Rheine
FHeart 3 MW
Meyer-Wittko
07:42:07
93.6
Precision
A Pure
T
0
5
10
14
MI
1.5
6C1
diffT5.0
14 fps
G:75
DR:55
DF 2.0
CG:23
4.9k
F:3

Ebstein Anomalie

* septales Segel

+ posteriores Segel

X atrialisierter RV

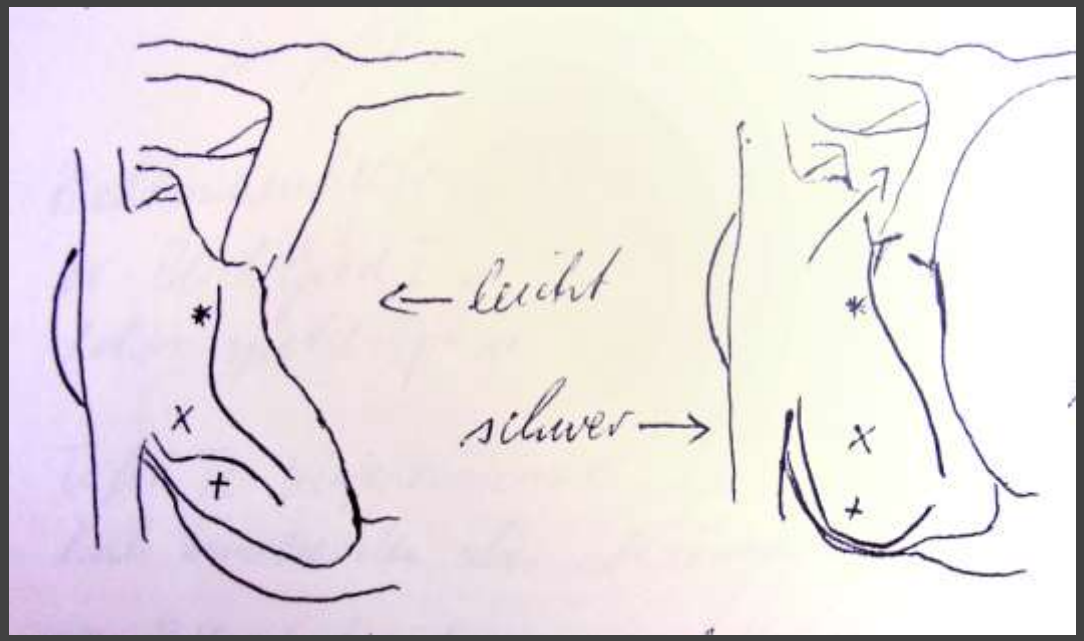

Figure 1

A pencil sketch of Wilhelm Ebstein published in the *Festschrift* celebrating Ebstein's 70th birthday. Published by permission of the Mayo Clinic Proceedings, where it was published by Mann RJ, Lie JT. The life story of Wilhelm Ebstein (1836–1912) and his almost overlooked description of a congenital heart disease. Mayo Clin Proc 1979;54:197–204.

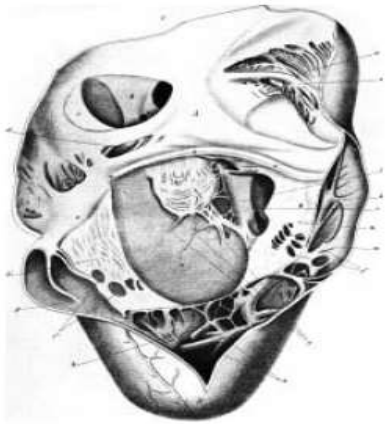

Figure 2

First figure of Ebstein's original case report. This figure shows right atrium and right ventricle opened along right border beginning at the superior vena cava. A = right atrium; B = right ventricle; b = valve not quite closing the foramen ovale, l = rudimentary septal leaflet of tricuspid valve with its chordae tendineae inserting on endocardium of ventricular septum; r = opening giving access to right conus arteriosus and, in the opposite direction, to the sac

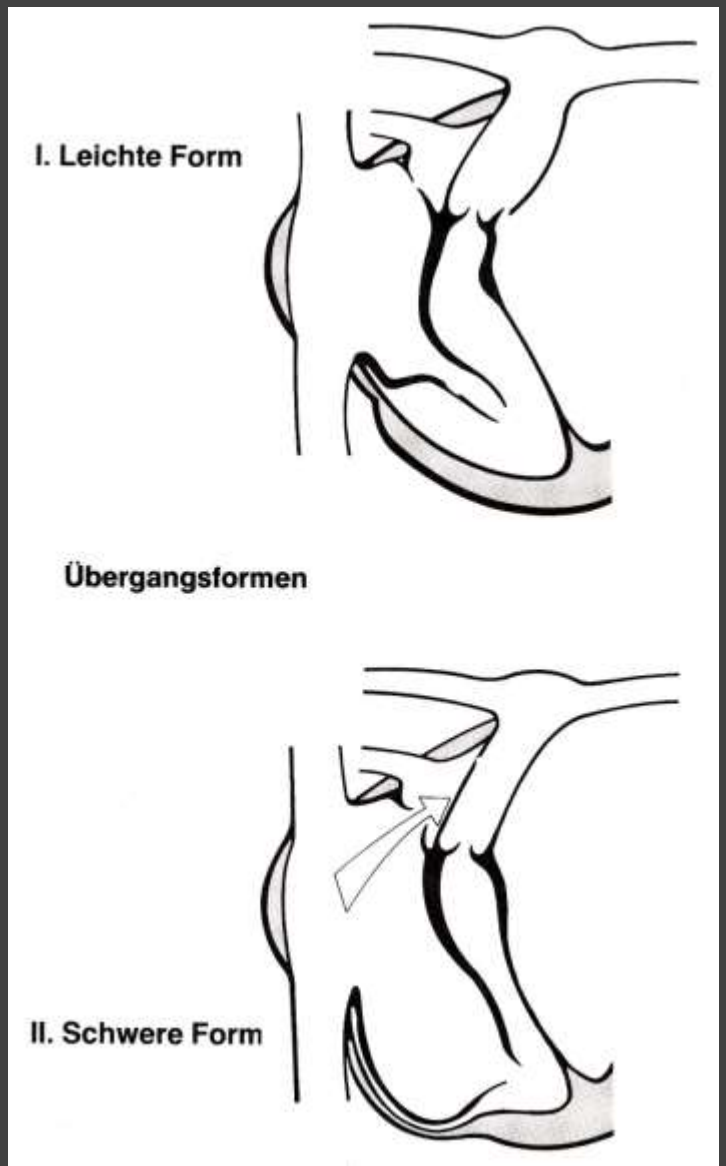

T
4
6
8
6C2
T5.0
48 fps
MI:1.0
2DG
83
DR
60
Storing
HDD:5% Free

0008318050 GA=38W1d
11.8cm / 93Hz
TIs 0.2
19.04.2007 11:44:41
COMP
Fetal Cardio
Har-mid
Pwr 100
Gn 2
C6 / M4
E2
SRI II 4 / CRI 2
REC
2.2 sec

TOSHIBA
Aplio i800
Mathias-Spital Rheine
OB 10C3
08:15:21
Precision+
A Pure
T
MI
1.2
10C3
d7.6
58 fps
Qscan
G:81
DR:55
A:1
P:4
5

Aplio 500
Mathias-Spital Rheine
FHeart 6 MW
13:34:36
Precision
A Pure
T
3
4
5
6
MI
1.2
10C3
diffT6.0
49 fps
Qscan
G:93
DR:55
A:3
P:2

Atrioventrikulärer Septumdefekt (AVSD)

Wenn der Mittelpunkt des Herzens fehlt

Prof. Dr. med. Herbert E. Ulmer, Heidelberg

Herzfehler-AVSD.pdf

Deutsche Herzstiftung e.V. (DE) https://www

Suchen

2 von 15 90%

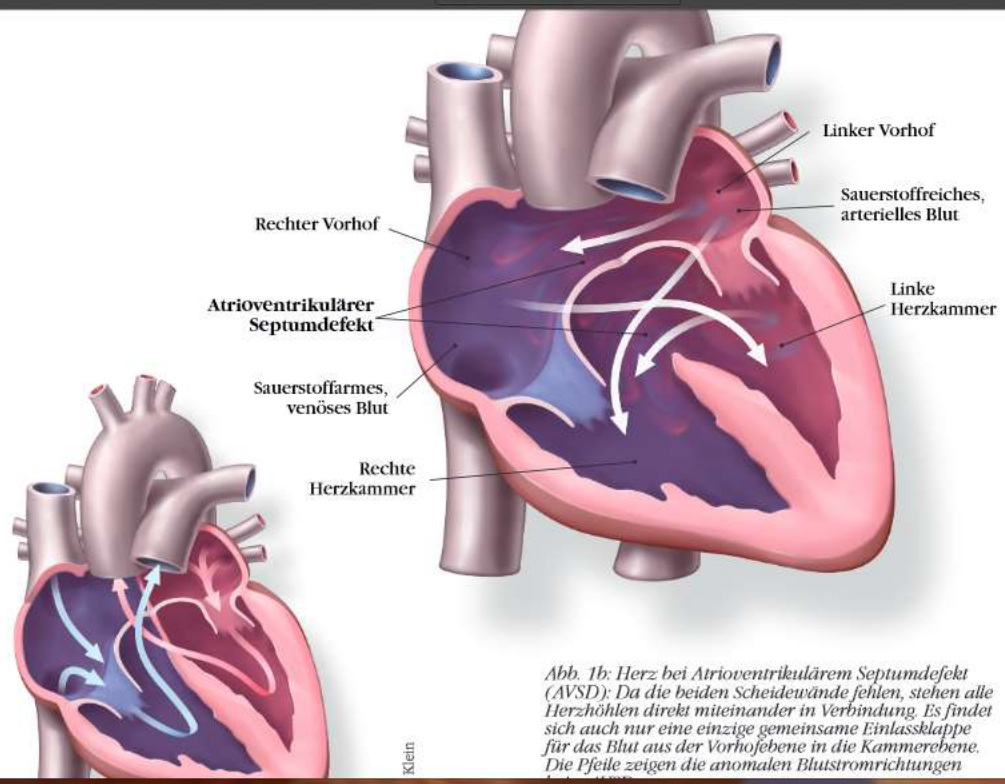

Abb. 1b: Herz bei Atrioventrikulärem Septumdefekt (AVSD): Da die beiden Scheidewände fehlen, stehen alle Herzhöhlen direkt miteinander in Verbindung. Es findet sich auch nur eine einzige gemeinsame Einlassklappe für das Blut aus der Vorhofebene in die Kammerebene. Die Pfeile zeigen die anomalen Blutstromrichtungen

Desktop 08:24 18.11.2017

ATRIOVENTRICULAR SEPTAL DEFECT

Definition, Spectrum of Disease, and Incidence

Complete atrioventricular septal defect (AVSD) is a cardiac malformation that combines an atrial septum primum defect and a ventricular septal defect with an abnormal common atrioventricular valve, which connects to the right and left ventricles (Fig. 15-20). The common atrioventricular valve usually has five leaflets. Synonyms for AVSD include endocardial cushion defect and atrioventricular canal defect. Partial AVSD includes an atrial septum primum defect and a cleft in the mitral valve. In partial AVSD, two distinct mitral and tricuspid valve annuli exist. AVSD can also be classified as balanced or unbalanced. In unbalanced AVSD the atrioventricular connection predominantly drains to one of the two ventricles, resulting in ventricular size disproportion. Unbalanced AVSD is typically found in association with heterotaxy syndrome (see Chapter 22).

AVSD results from failure of fusion of the endocardial cushions during embryogenesis of the heart. It is a common cardiac malformation found in 4% to 5% of all infants with congenital heart disease and occurs in 0.19 per 1000 live births (23,24). AVSD is also commonly diagnosed in the fetus, accounting for 18% of cardiac abnormalities in one large series (4). AVSD is slightly more common in girls (23) and has a high association with chromosomal abnormalities, primarily Down syndrome. Figure 15-21 represents an anatomic specimen of a fetal heart with AVSD.

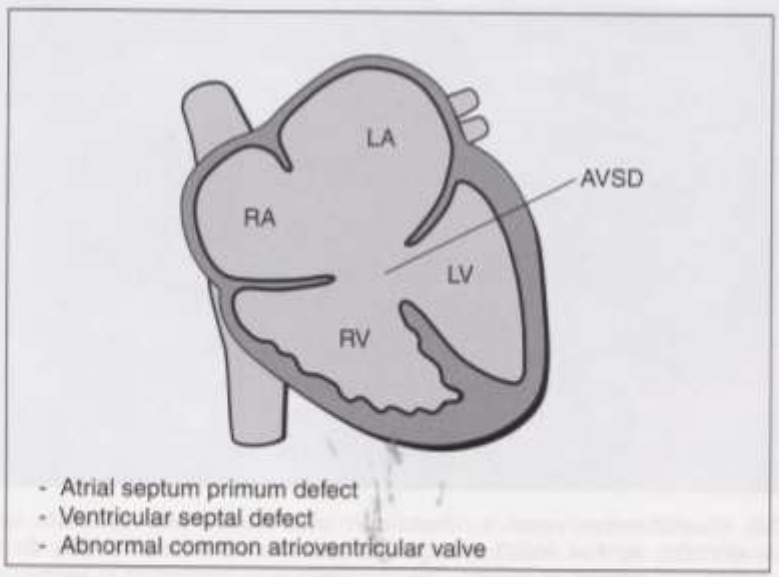

Figure 15-20. Atrioventricular septal defect (AVSD). RA, right atrium; RV, right ventricle; LV, left ventricle; LA, left atrium.

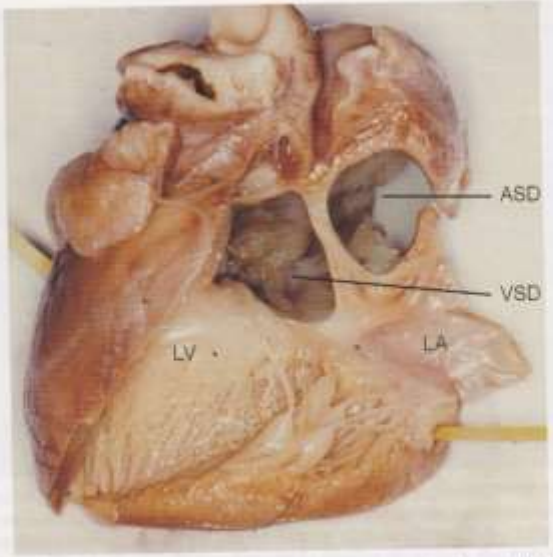

Figure 15-21. Anatomic specimen of a fetal heart with atrioventricular septal defect. The heart is opened from the left atrium (LA) and left ventricle (LV). Large interatrial septum primum defect (ASD) as well as an interventricular septal defect (VSD) are seen.

Ultrasound Findings

Gray Scale

AVSD is best detected in the apical four-chamber view. In diastole, when the common valve is open, a defect in the center of the heart (also referred to as *crux*) can be identified due to lack of tissue (Fig. 15-22). This defect in the center of the heart results from the large atrial and

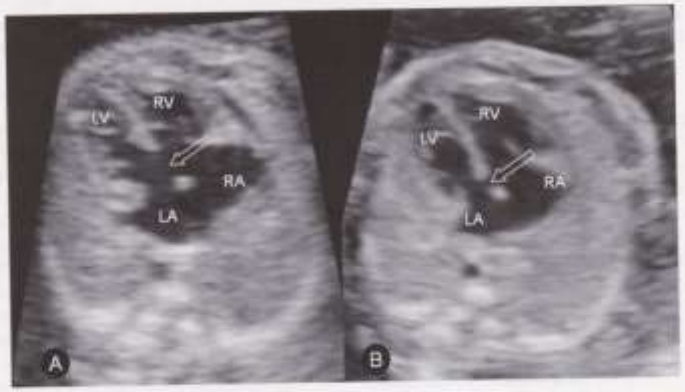

Figure 15-22. Four-chamber views in diastole in two fetuses with complete atrioventricula septal defects (AVSDs). **A:** The AVSD is large and clearly visible (*open arrow*). **B:** The AVSD i small (*open arrow*) and difficult to detect. The diagnosis was confirmed in systole owing to th linear insertion of the valves as seen in Figure 15-23. LA, left atrium; LV, left ventricle; RA, righ atrium; RV, right ventricle.

Vergrößern

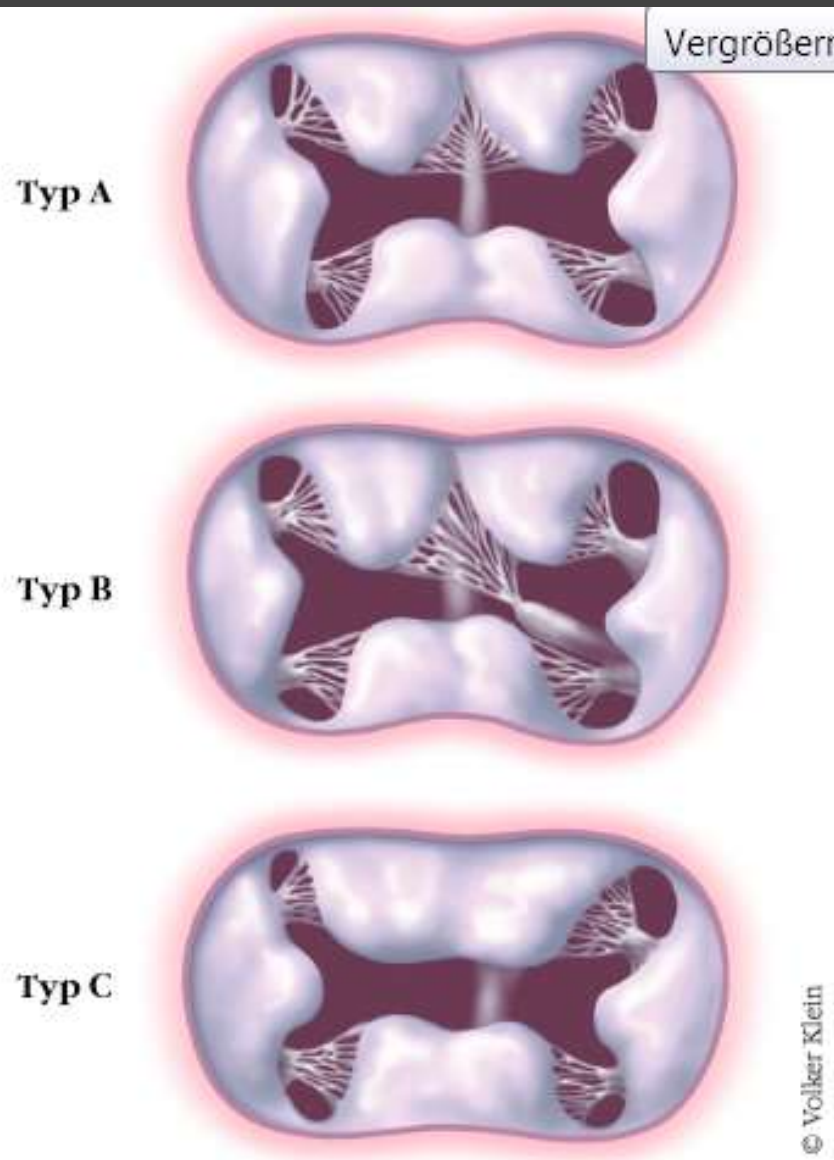

Abb. 2b: Aufsicht auf die drei Typen der anomalen gemeinsamen AV-Klappe beim AVSD in der Klassifikation nach Rastelli (Einzelheiten siehe Text)

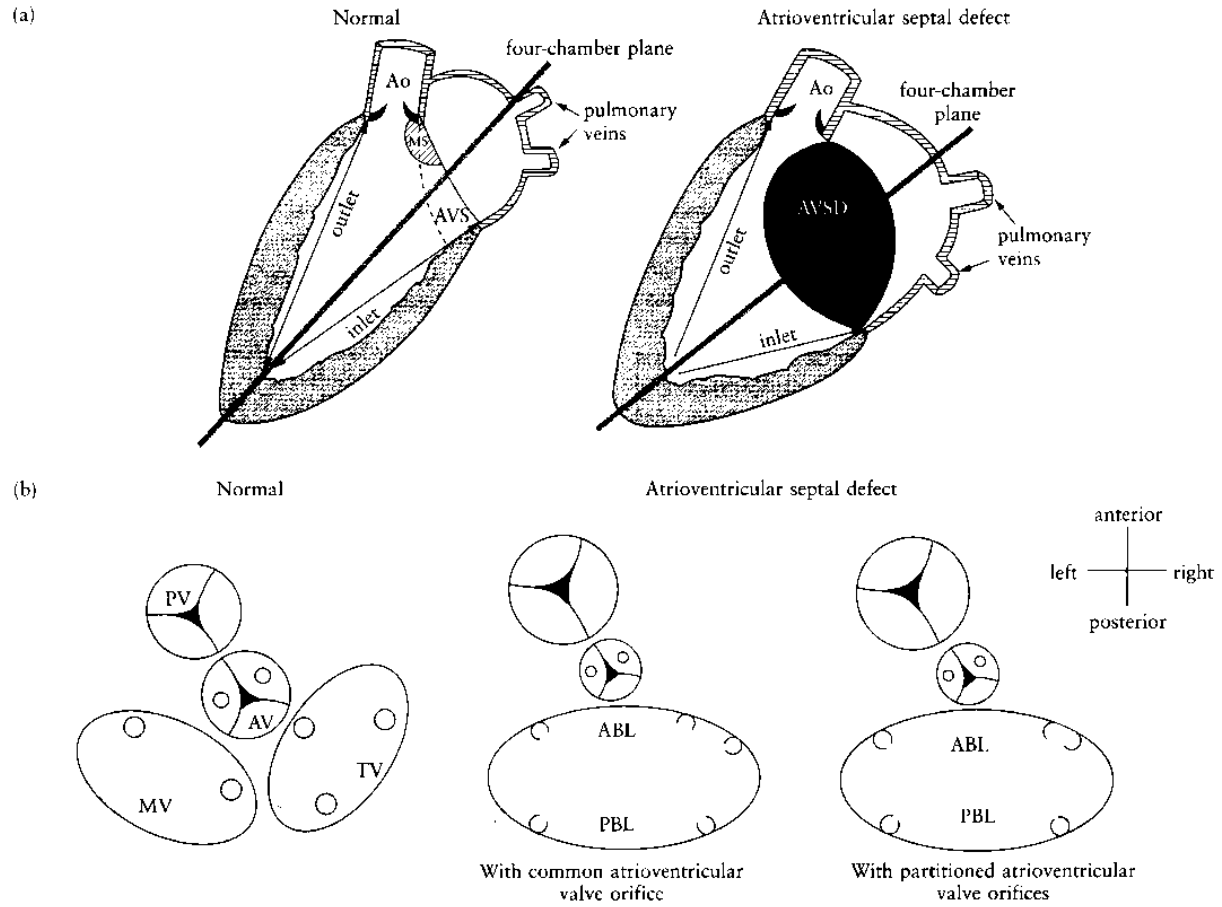

Figure 1 Diagrams illustrating unifying features of atrioventricular septal defect (AVSD). (a) Atrial and ventricular septum seen from the left ventricle after removal of the free wall of the left atrium and left ventricle and the mitral valve leaflets. (b) Atrioventricular junction seen from above after removal of the atria and great arterial trunks above the cardiac valves. In a normal heart, the tricuspid valve has a more apical attachment to the septum (solid line in (a), left) than does the mitral valve (interrupted line). The atrioventricular septum (AVS) is present between the right atrium and left ventricle because of this off-set attachment of the tricuspid and mitral valves to the septum. AVSD is characterized by a large defect involving the whole atrioventricular septum and adjacent ventricular and atrial septa, short inlet and elongated outlet with an inlet–outlet disproportion, and a common atrioventricular junction or annulus. The aortic valve (AV) is deeply wedged between the mitral (MV) and tricuspid (TV) valves in the normal heart. Hearts with an AVSD have a common atrioventricular valve annulus regardless of whether the atrioventricular valve orifice is partitioned. The common atrioventricular valve annulus does not allow the aortic valve to have a wedged position. Because of this unwedged position of the aortic valve, the left ventricular outflow tract is elongated. When a normal heart is scanned along a four-chamber plane perpendicular to the gray line in (a), the atrial length is approximately 50% of the ventricular length. When a heart with AVSD is scanned in a four-chamber view, the atrial length is only slightly shorter than the foreshortened ventricular length. The scooped-out ventricular septal crest with apically displaced bridging leaflets makes the ventricular inlet look even shorter in a regular four-chamber view. ABL, anterior bridging leaflet; Ao, aorta; MS, membranous septum; PBL, posterior bridging leaflet; PV, pulmonary valve.

Copyright © 2004 ISUOG. Published by John Wiley & Sons, Ltd.

TOSHIBA
Aplio i800
Mathias-Spital Rheine
OB 10C3
08:15:57
Precision+
A Pure
T
MI
1.2
10C3
d7.6
92 fps
Qscan
G:81
DR:55
A:1
P:4
3
4
5

T
2
4
6
6C2
T5.0
38 fps
MI:1.2
2DG
87
DR
60
Storing
HDD:28% Free
SELECT

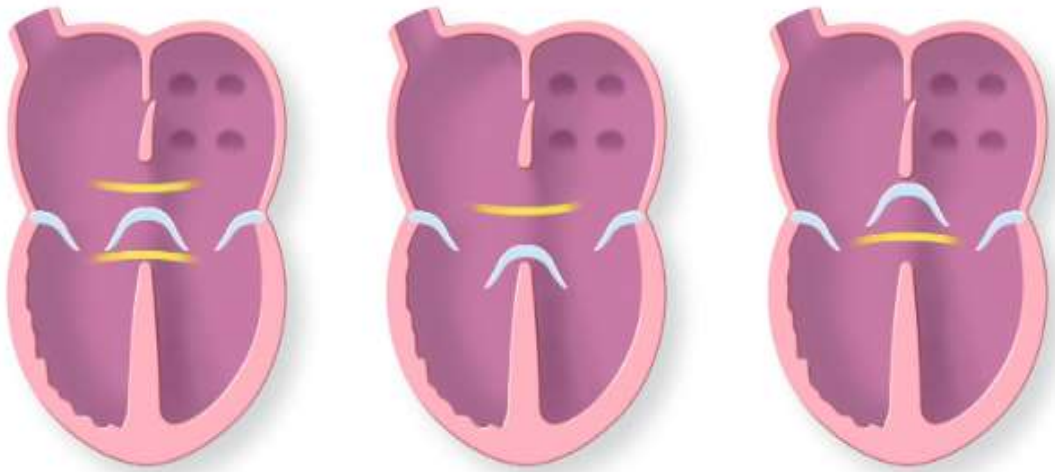

© Volker Klein

A
Shunt in Vorhof- und Ventrikelebene

B
Shunt in Vorhofebene

C
Shunt in Ventrikelebene

Abb. 3: Möglichkeiten der Aufhängung der Brückensegel der gemeinsamen AV-Klappe beim AVSD: In der Regel zeigt das Brückensegel keine Anheftung an Teile der Scheidewand (A), sodass Blut sowohl in Vorhof- als auch in Ventrikelebene nach beiden Seiten des Herzens shunten (kreuzen) kann. Ist das Brückensegel mit dem Oberrand des Restes der Kammerscheidewand verbunden (B), dann erfolgt ein Shunt (Blutkreuzen) nur in Vorhofebene. Liegt eine Fixierung des Brückensegels am unteren Rand der unvollständigen Vorhofscheidewand vor (C), resultiert ein großer Shunt in Kammerebene.

Desktop

Ultrasound Obstet Gynecol 2014; 44: 568–574
Published online in Wiley Online Library (wileyonlinelibrary.com). DOI: 10.1002/uog.13326

Differential and linear insertion of atrioventricular valves: a useful tool?

B. M. E. ADRIAANSE*†, M. M. BARTELINGS†, J. M. G. VAN VUGT‡, R. CHAOUI§, A. C. GITTENBERGER-DE GROOT¶ and M. C. HAAK**

*Department of Obstetrics and Gynecology, VU University Medical Center, Amsterdam, The Netherlands; †Department of Anatomy and Embryology, Leiden University Medical Center, Leiden, The Netherlands; ‡Department of Obstetrics and Gynecology, Radboud University Medical Center, Nijmegen, The Netherlands; §Center for Prenatal Diagnosis and Human Genetics, Berlin, Germany; ¶Department of Cardiology, Leiden University Medical Center, Leiden, The Netherlands; **Department of Obstetrics and Gynecology, Leiden University Medical Center, Leiden, The Netherlands

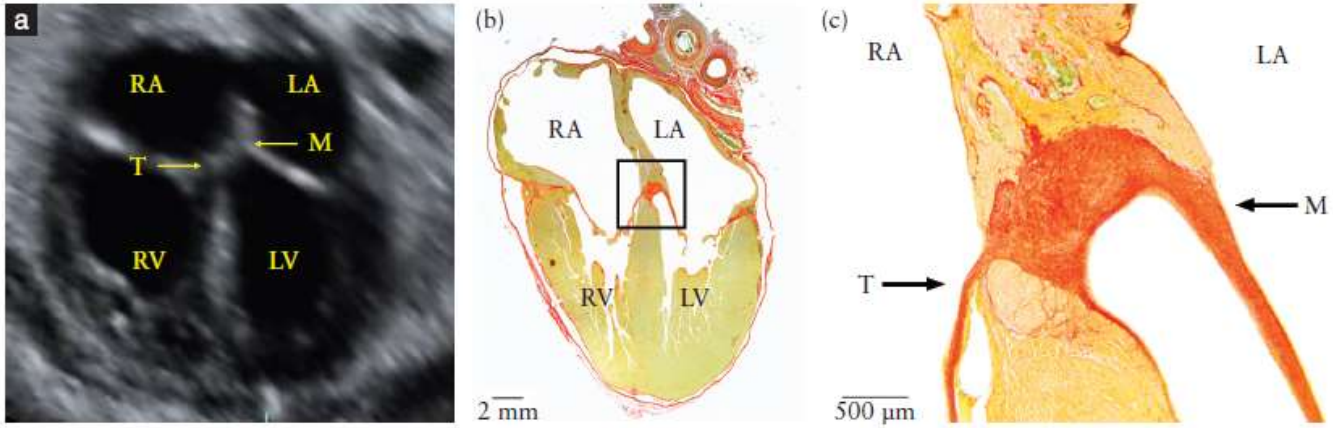

Figure 2 (a) Spatiotemporal image correlation ultraso
showing four-chamber view obtained at the level imm
atrioventricular valves (DIAVV) can be seen. (b) Histo
gestation. (c) Enlargement of the box in (b), showing t
right ventricle; T, tricuspid valve.

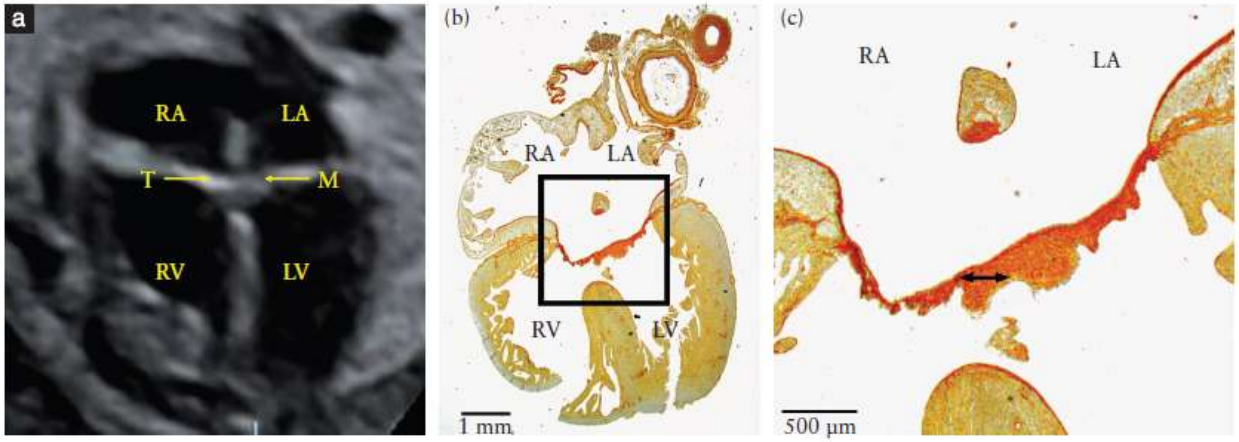

Figure 5 (a) Spatiotemporal image correlation ultrasound image of a fetal heart at 18 weeks' gestation with an atrioventricular septal defect (AVSD), showing four-chamber view obtained at level 1 (immediately beneath the aortic outflow tract), in which linear insertion of the atrioventricular valves (LIAVV) can be seen. (b) Histological section, equivalent to that shown in (a), of a fetal heart at 14 weeks' gestation with an AVSD. (c) Enlargement of the box in (b), showing LIAVV. LA, left atrium; LV, left ventricle; M, mitral valve; RA, right atrium; RV, right ventricle; T, tricuspid valve.

TOSHIBA
Aplio i800
Mathias-Spital Rheine
OB 10C3
08:23:46
Precision+
A Pure
T
MI
1.2
10C3
d7.1
54 fps
Qscan
G:81
DR:55
A:1
P:4
3
4
5
6

Herzfehler-AVSD.pdf
Deutsche Herzstiftung e.V. (DE) https://www
Suchen
6 von 15 100%

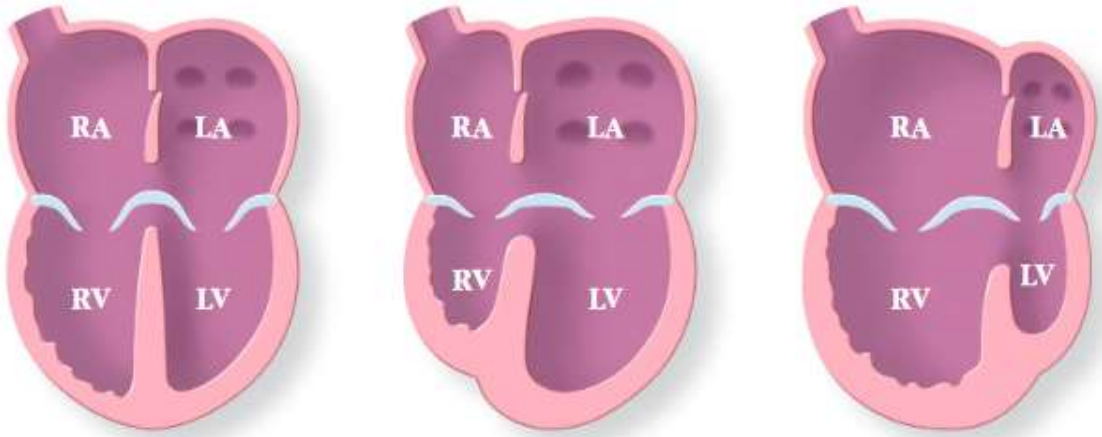

© Volker Klein

A
Balancierte Form

B
Links-Dominanz

C
Rechts-Dominanz

Abb. 4: Möglichkeiten einer ungleichmäßigen Entwicklung der beiden Herzkammern (Ventrikel-Imbalance) beim AVSD; A: beide Kammern gleich entwickelt = balancierte Form; B: rechte Kammer unterentwickelt = Links-Dominanz; C: linke Kammer unterentwickelt = Rechts-Dominanz
Abkürzungen: RA = rechter Vorhof; LA = linker Vorhof; RV = rechte Kammer; LV = linke Kammer

Desktop

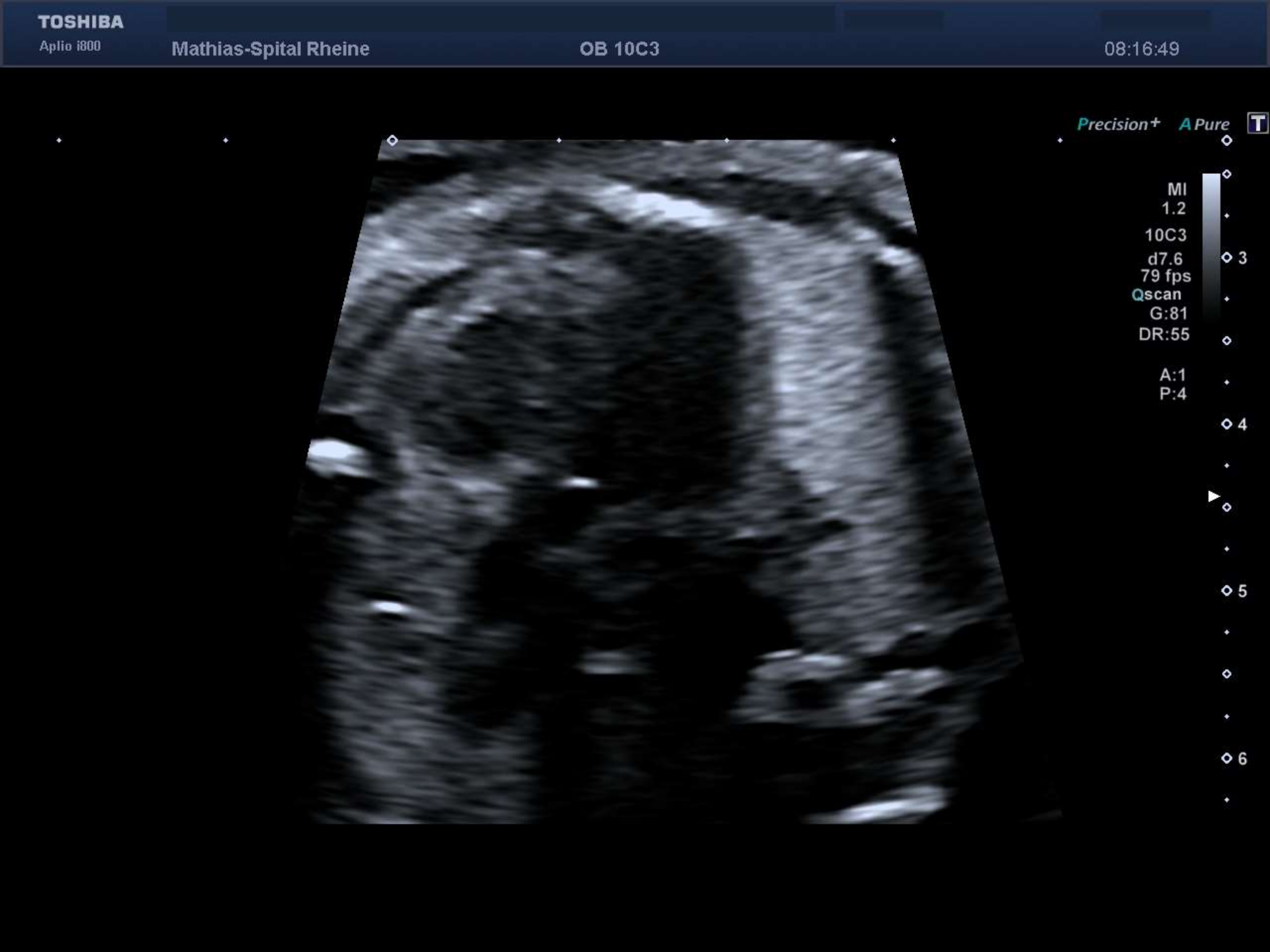
TOSHIBA
Aplio i800
Mathias-Spital Rheine
OB 10C3
08:16:49
Precision+
A Pure
T
MI
1.2
10C3
d7.6
79 fps
Qscan
G:81
DR:55
A:1
P:4
3
4
5
6

T
2
4
6
6C2
T5.0
36 fps
MI:1.2
2DG
88
DR
60
Storing
HDD:22% Free
SELECT

Kardiale Fehlbildungen

Herzfehlbildungen betreffen 4–8 Kinder von 1000 Lebendgeburten. Damit stehen die Fehlbildungen des Herzens – unabhängig von ihrer Spezifikation – an erster Stelle. Die häufigsten Herzfehler sind:

- Ventrikelseptumdefekt: 32%,
- Pulmonalisstenose: 9%,
- Vorhofseptumdefekt: 8%,
- AV-Kanal: 7%,

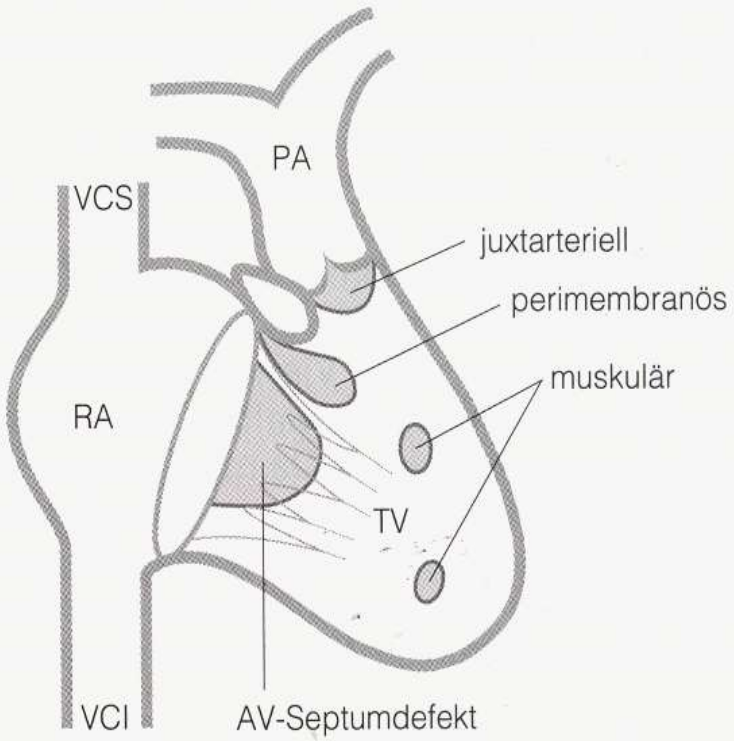

Schematische Darstellung der topografischen Anatomie der unterschiedlichen Ventrikelseptumdefekte (Blick auf die rechtsventrikuläre Seite des Ventrikelseptums).

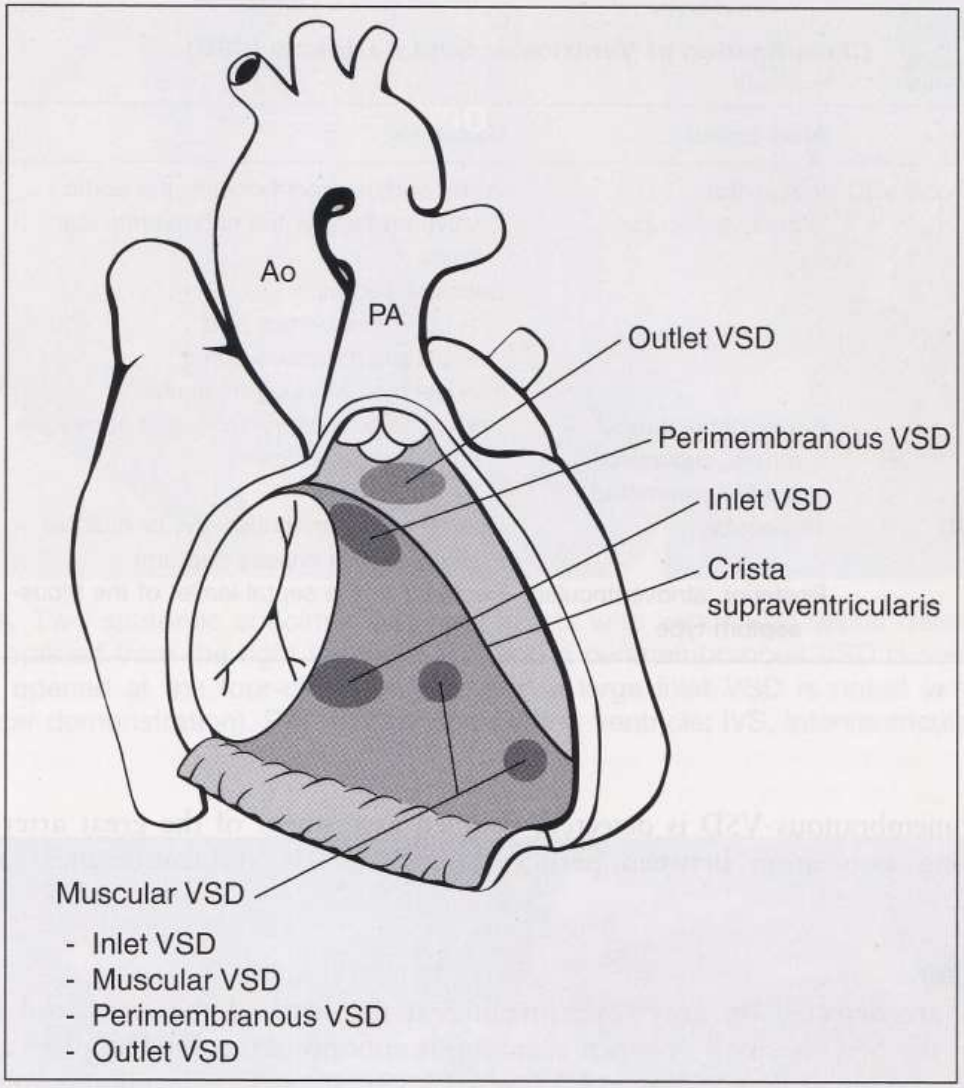

Figure 15-7. Ventricular septal defect (VSD)—types and anatomic locations as seen from the right ventricle. PA, pulmonary artery; Ao, aorta.

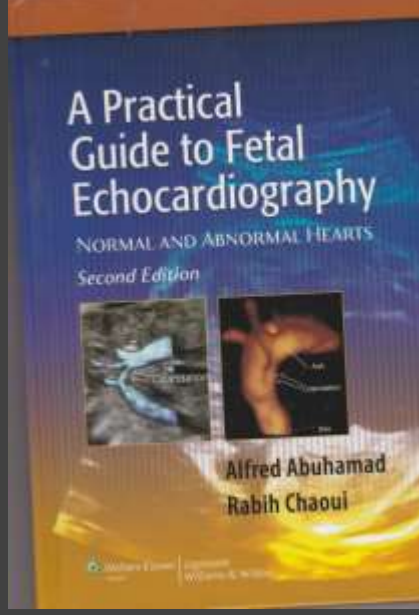

T
2
4
6
8
10C3
T7.6
39 fps
MI:1.2
2DG
77
DR
60
Dist A 0.0 mm
HDD:90% Free

right ventricle; PA, pulmonary artery; Ao, aorta.

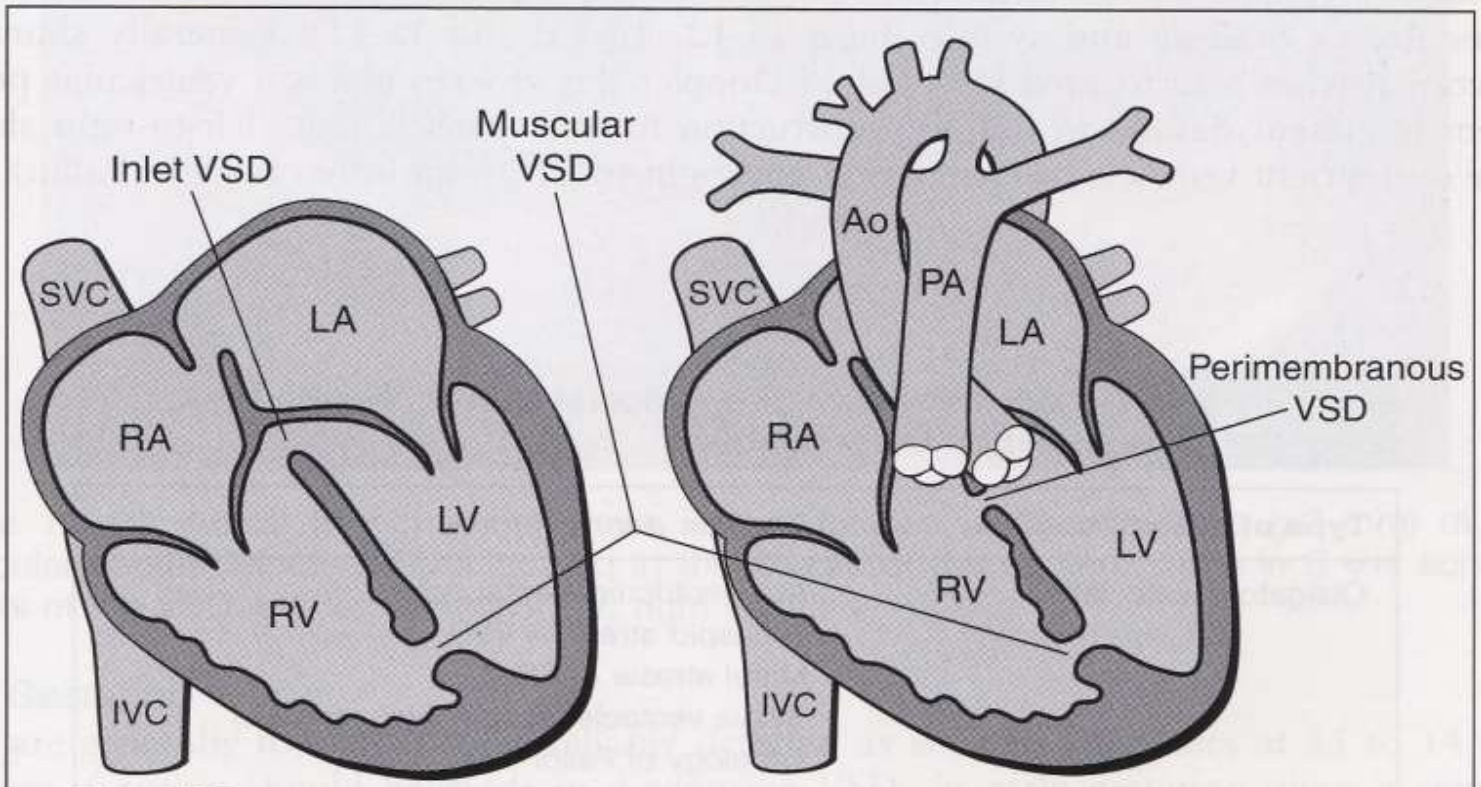

Figure 15-8. Ventricular septal defect (VSD)—anatomic locations as seen at the level of the four-chamber view and the outflow tracts. Ao, aorta; RA, right atrium; RV, right ventricle; LA, left atrium; LV, left ventricle; SVC, superior vena cava; IVC, inferior vena cava.

T
4
6
8
10
6C2
T5.0
24 fps
MI:1.2
2DG
82
DR
60
HDD:9% Free

.86
.86
9:15:35 am
4V2
17Hz
H4.0MHz
R30mm
NTHI OB
NTHI OB
T2/-1/ 2/V:3
1/2
CD:2.5MHz
CD Gain = 50
Store in progress
-0:10:08
CDE/CDV
CD Pan
CD Pos/Size

T
2
4
6
8
10C3
T7.6
32 fps
MI:1.3
2DG
79
DR
60
HDD:76% Free

T
2
4
6
6C2
T5.0
38 fps
MI:1.2
2DG
79
DR
60
HDD:65% Free

Univentrikuläres Herz

Heterogene Pathoanatomie :
Double-inlet ventrikel; Atresie einer AV-Klappe (Trikuspidalatresie);
Atresie einer Semilunarklappe;...
funktionell univentrikuläres Herz bei Hypoplasie eines Ventrikels

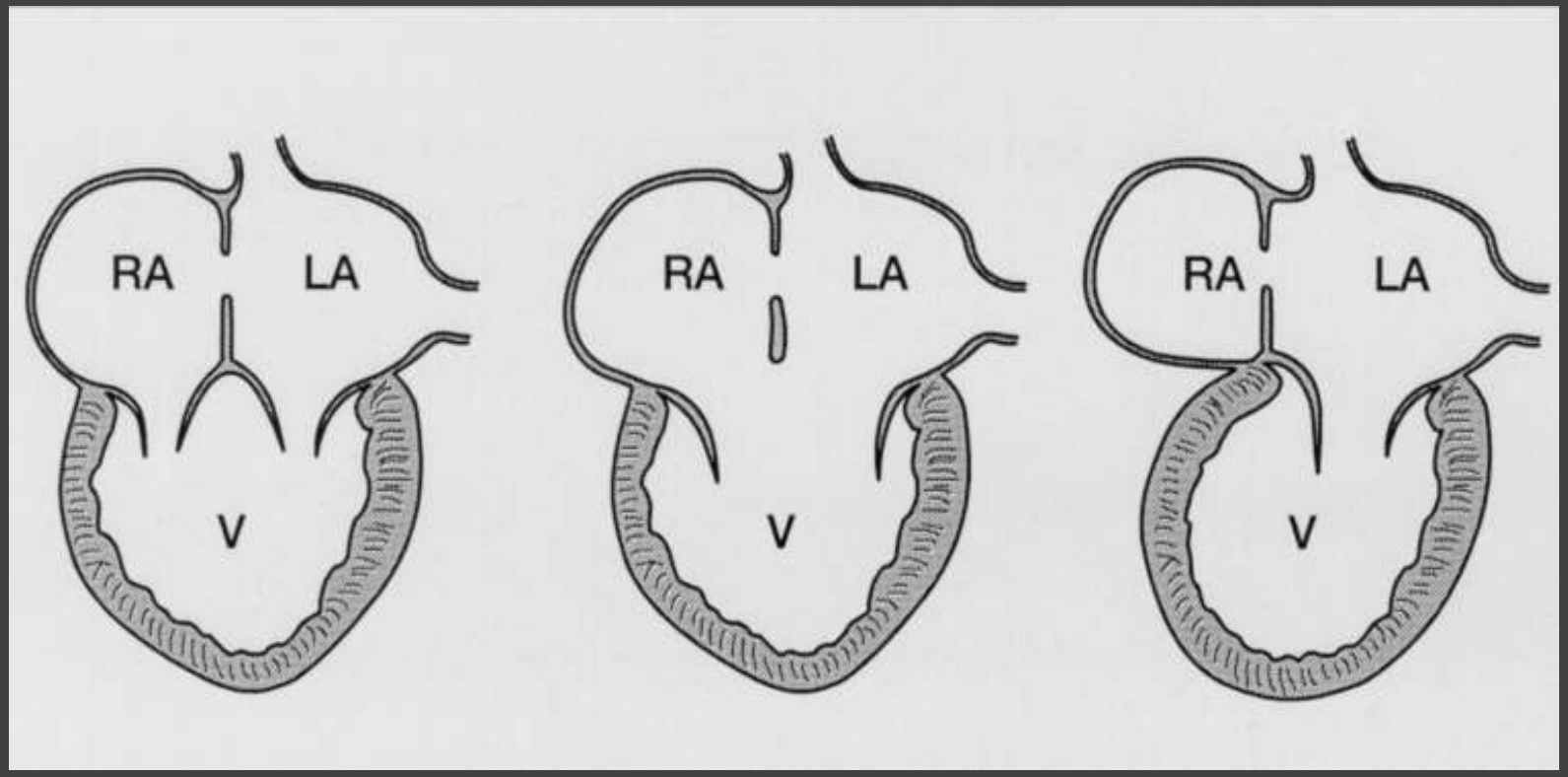

T
4
6
8
MI:1.0
2DG
80
DR
60
6C2
T5.0
41 fps
HDD:8% Free
SELECT

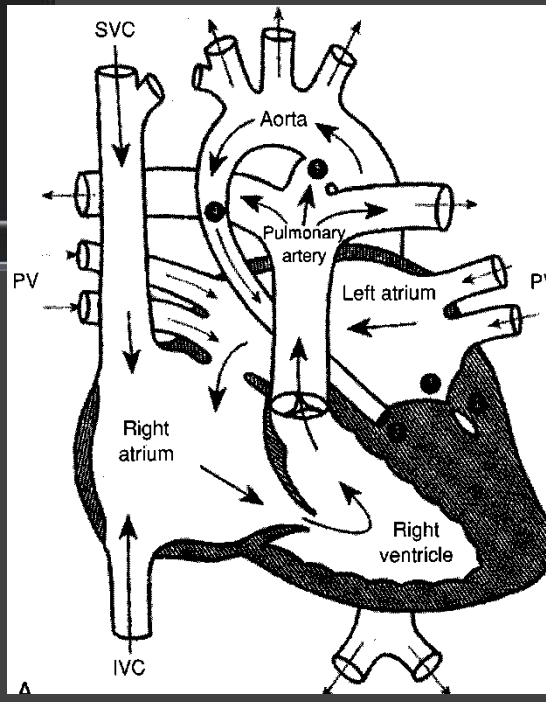
SVC
Aorta
Pulmonary
artery
PV
Left atrium
Right
atrium
Right
ventricle
IVC

Precision
A Pure
T
MI
1.2
10C3
diffT6.0
63 fps
Qscan
G:97
DR:55
A:3
P:2
5

Häufigkeitsverteilung angeborener Herzfehler postnatal

Herzfehler	Lebend-geburten
Ventrikelseptumdefekt	32%
Pulmonalstenose	9%
Atrioventrikulärer Septumdefekt (AVSD)[a]	7%
Aortenisthmusstenose	5%
Fallot-Tetralogie	7%
Hypoplastisches Linksherzsyndrom (HLHS)[a]	4%
d-Transposition der großen Arterien	5%
Aortenklappenstenose	3%
„Univentrikuläres Herz" (Double Inlet etc.)[a]	2–3%
Double Outlet Right Ventricle (DORV)	2%
Pulmonalklappenatresie bei intaktem Ventrikelseptum[a]	2%
Truncus arteriosus	1%

(Hoffman, Pediatr Cardiol 1995)

20 SSW ohne Farbdoppler

89.8
97.6
cm/s
2
3
5
6C2
T5.0
CF 3.0
16 fps
2DG
87
DR
60
CG
29
PRF
7.5k
Filter
3
Storing
HDD:10% Free
SELECT

26 SSW

33 SSW

Pure
T
2
4
6
10C3
diffT6.0
64 fps
MI:1.0
2DG
77
DR
55
A 2 IP2
HDD:36% Free
Raw Memory:#0(0%)

Storing HDD:17% Free SELECT

NIK - - MWNEUNOCH BESSER 1 07.04.2006 14:07:17

HDD:71% Free ABC

T
65.5
65.5
cm/s
5
6
10C3
T7.6
CF 3.8
23 fps
2DG
71
DR
65
CG
36
PRF
6.5k
Filter
3
HDD:71% Free
SELECT

1
2

MI:1.0
2DG
85
DR
60
% Free
SELECT

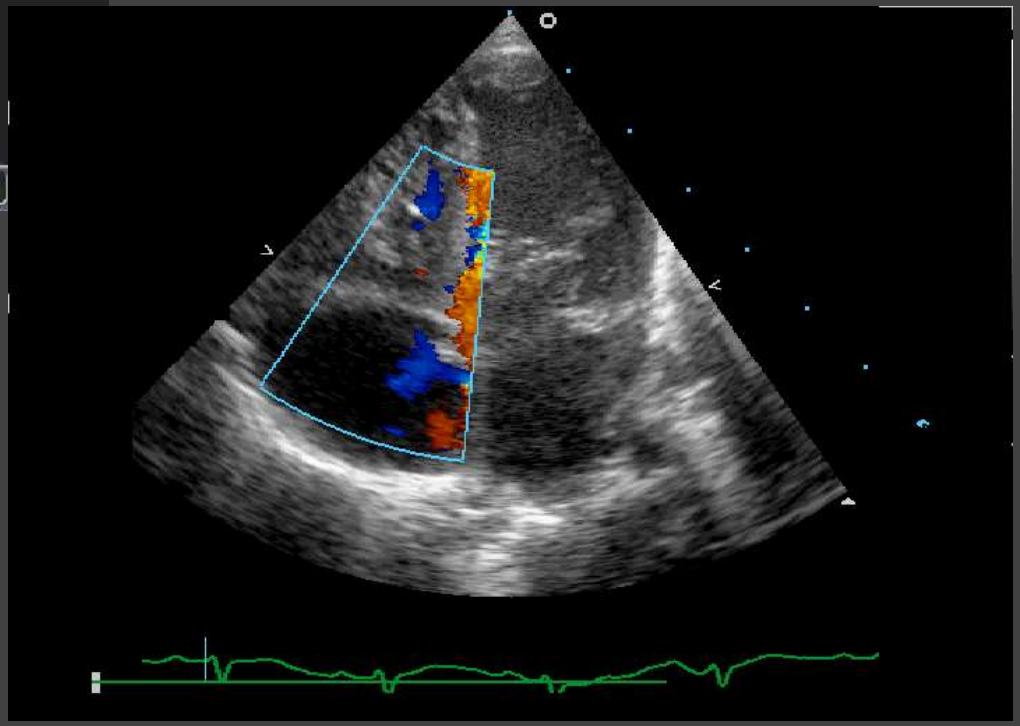

Precision
Pure
T
4
6
8
10C3
diffT6.0
60 fps
MI:0.7
2DG
77
DR
55
A 3 IP2
Storing
HDD:21% Free
Raw Memory:#0(0%)

right ventricle; PA, pulmonary artery; Ao, aorta.

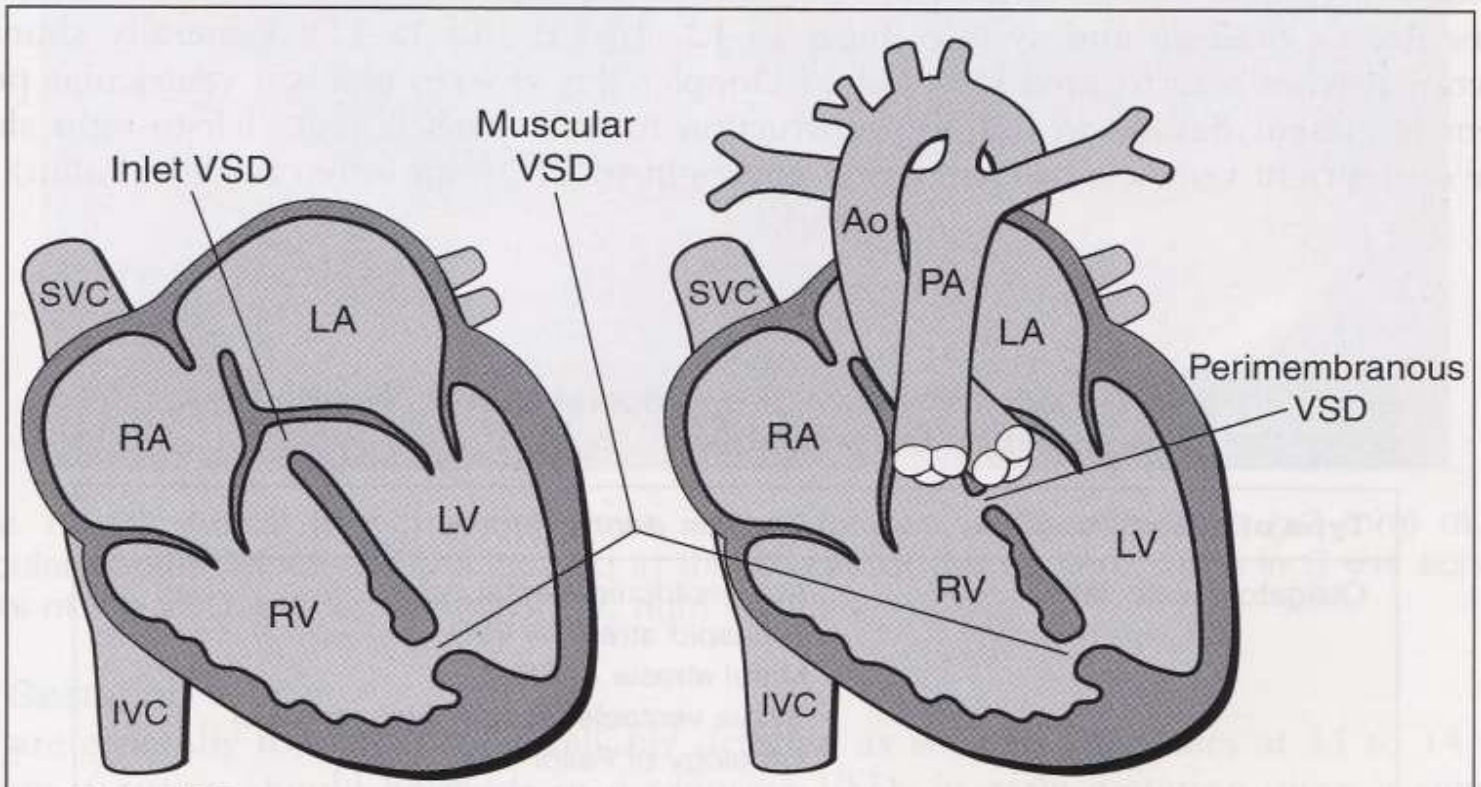

Figure 15-8. Ventricular septal defect (VSD)—anatomic locations as seen at the level of the four-chamber view and the outflow tracts. Ao, aorta; RA, right atrium; RV, right ventricle; LA, left atrium; LV, left ventricle; SVC, superior vena cava; IVC, inferior vena cava.

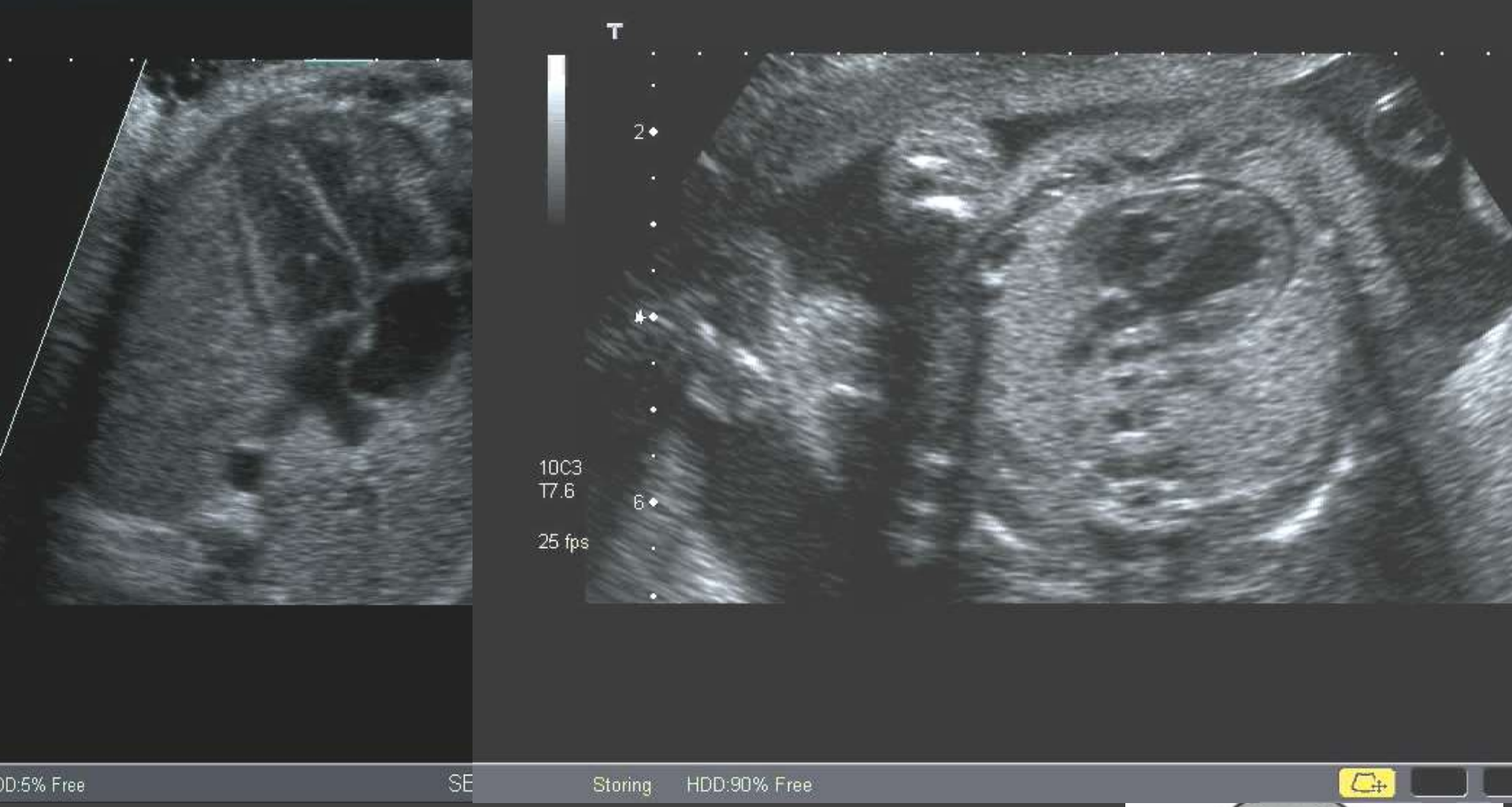

- Kontinuität zwischen anteriorem Mitralklappensegel und Aortenhinterwand

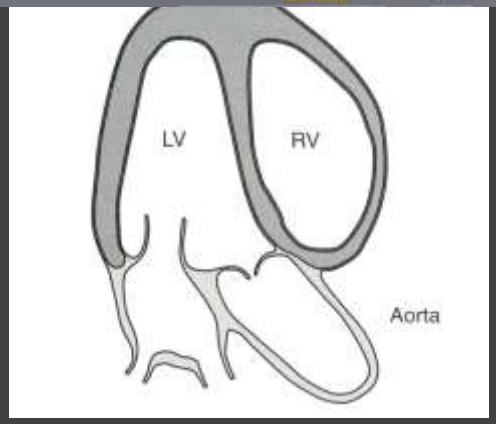

Aplio 500
Klinikum Oldenburg Frauenklin.
Fetal Heart
STEUERNAG
13:48:54
Precision
A Pure
T
MI
1.2
10C3
diffT6.0
58 fps
G:85
DR:55
A:3
P:1
5

E8
Exp
10525244
7.1cm / 1.3 / 39Hz
TIs 0.1
13.02.2014
09:58:02
Voluson
E8
fetales Herz
Har-high
100
Gn 2
C9 / M7
FF1 / E2
SRI II 4 / CRI 3

T
4
6
8
MI:1.1
2DG
80
DR
60
6C2
T5.0
20 fps
HDD:85% Free

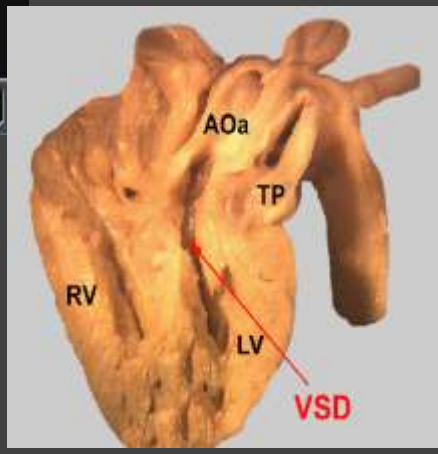
AOa
TP
RV
LV
VSD

Lernmedien

- **Bücher/CD** (immer Kombination!)
  - Die fetale Echokardiographie, C. Berg
  - Hecher, Steiner , Gembruch Ultrschalldiagnostik 2017
- **Online-Fortbildung www.fetal.ch**
  - ISUOG (größte Sammlung an Vorträgen)



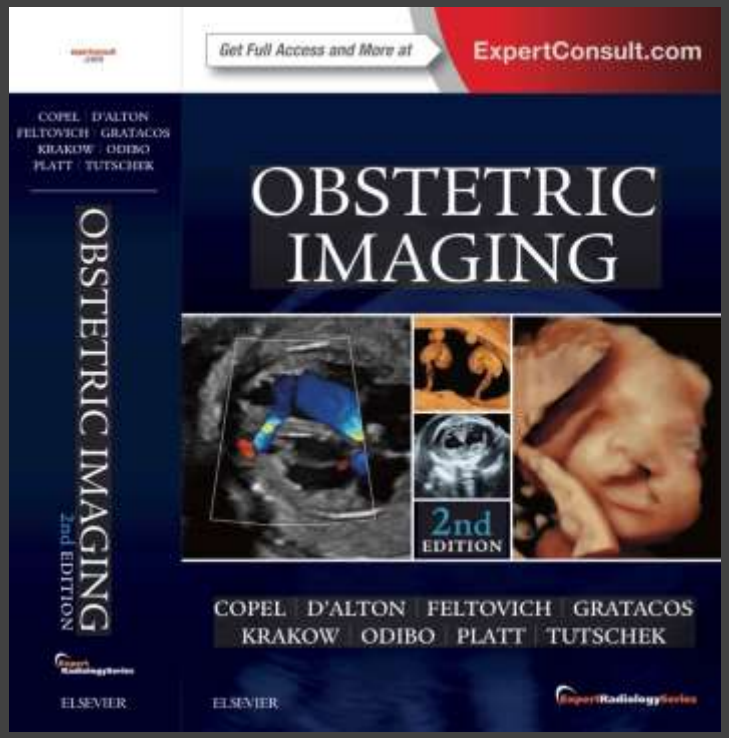

Circulation

American Heart Association.

Diagnosis and Treatment of Fetal Cardiac Disease: A Scientific Statement From the American Heart Association

Mary T. Donofrio, Anita J. Moon-Grady, Lisa K. Hornberger, Joshua A. Copel, Mark S. Sklansky, Alfred Abuhamad, Bettina F. Cuneo, James C. Huhta, Richard A. Jonas, Anita Krishnan, Stephanie Lacey, Wesley Lee, Erik C. Michelfelder, Sr. Gwen R. Rempel, Norman H. Silverman, Thomas L. Spray, Janette F. Strasburger, Wayne Tworetzky and Jack Rychik on behalf of the American Heart Association Adults With Congenital Heart Disease Joint Committee of the Council on Cardiovascular Disease in the Young and Council on Clinical Cardiology, Council on Cardiovascular Surgery and Anesthesia, and Council on Cardiovascular and Stroke Nursing

Circulation. 2014;129:2183-2242; originally published online April 24, 2014;
doi: 10.1161/01.cir.0000437597.44550.5d
Circulation is published by the American Heart Association, 7272 Greenville Avenue, Dallas, TX 75231
Copyright © 2014 American Heart Association, Inc. All rights reserved.
Print ISSN: 0009-7322. Online ISSN: 1524-4539

Danke für`s Zuhören

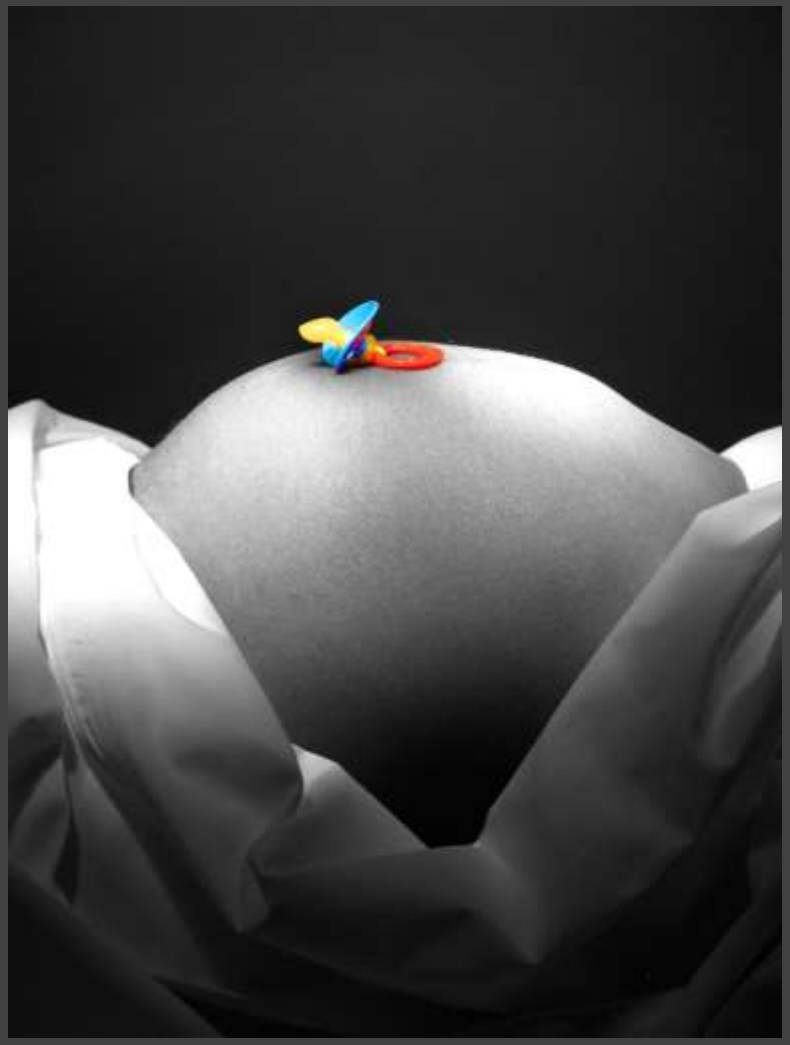

Folien bei m.meyer-wittkopf@mathias-spital.de